

## **SURGICAL CORRECTION OF THIRD-DEGREE RECTOVESTIBULAR LACERATIONS IN EQUINE**

**G. I. A. Karrouf and A. E. I. Zaghloul**

Dept. of Surgery, Anesthesiology and Radiology, Fac. of Vet. Med.,

Mansoura University, Egypt

### **ABSTRACT**

*Six mares and a she donkey suffering from third-degree rectovestibular lacerations had been admitted to the Surgery Clinic, Faculty of Veterinary Medicine, Mansoura University. These injuries occurred during parturition associated with dystocia. Six of these animals were primiparous and a mare was nulliparous. Surgical correction of these lacerations were performed through a single-stage repair of the modified Goetz technique by interrupted six-bite vertical mattress pattern using polydioxanone monofilament synthetic absorbable suture material (PDS, Ethicon). Primary healing of the reconstructed rectovestibular shelves and perineal bodies were occurred in 6 animals although a mare showed a remarkable anal sphincter incompetence while dehiscence of the reconstructed rectovestibular septum with intact perineal body was recorded in a mare owing to sever post-operative straining resulting in a rectovestibular fistula formation. The obtained results indicated that surgical interference of third-degree rectovestibular lacerations should be postponed up to 5-7 weeks after initial injuries. Surgical correction of these disorders was successfully performed through a single stage repair using interrupted six-bite vertical mattress sutures with PDS. The control of vaginal and uterine infection as well as the supplement of soft diet were essential for good healing of the rectovestibular lacerations.*

### **INTRODUCTION**

Lacerations of the vulva and vagina result from dystocia, malpositioned fetus and abusive, hasty or excessively forceful efforts to assist delivery by mutation, fatotomy and traction. It is commonly occurred in mares when the foal's front foot or nose catches the annular fold of the hymen at the vaginovestibular junction (Walker & Vaughan, 1980; Aanes, 1988; and Emberton 1990). They may vary from simple tear in the dorsal commissure of the vulva to third degree lacerations that extend into the rectum.

Third-degree lacerations of the perineum are those violate the perineal body and contiguous walls of the vagina and rectum. The injury usually occurs in primiparous mares and seemingly more often in excitable temperament (Vaughan, 1988 and Trotter, 1992).

The goal of all surgical procedures is being reconstruction of a shelf between the rectum and vestibule and restoration of a functional perineal body (Straub & Fowler, 1961; Aanes, 1962 & 1964; Vaughan, 1986 & 1988 and Aanes, 1988). The principles that need to be observed and fulfilled include broad tissue apposition with minimal tension on the suture line. The most common methods are the single stage repair using a modification of the original Goetz method (Straub & Fowler, 1961; Stickle et al., 1979; Vaughan, 1986 and Embertson, 1990) and the two stage repair (Ansari & Martos, 1983; Colbern et al., 1985 and Aanes, 1988).

The bowel movement should be sufficiently soft and reduced in volume for one week before surgical procedure and for at least two weeks postoperatively accounting for a total time of about 3 weeks on a restricted diet of green fodder and bran mash. Painful or difficult defecation was responsible as errors of the technique for surgical failure (Vaughan, 1984 and McKinnon, et al., 1991).

The purpose of this study was to revise the important clinical and surgical aspect of this disorder as well as to evaluate the different alternatives of either immediate or delayed single-stage operation for their repair using polydioxanone synthetic monofilament absorbable suture in six bite interrupted vertical mattress sutures in both mares and she donkey.

### **MATERIALS AND METHODS**

Six cross breed mares and a she donkey of about 3-7 years old with a history of sever injuries in the perineal regions following dystocia were admitted to the Surgery Clinic of the Fac. of Vet. Med., Mansoura University. The affected animals were thoroughly examined after manual restraint and sedation using combelen in a dose of 0.15-0.20 mg/kg.B.W. The examination revealed a third-degree rectovestibular lacerations in all animals. The time elapsed between rectovestibular injuries and repair ranged from 5-7 weeks. One mare and a she donkey received an immediate surgical interference.

#### **Pre-surgical Preparation :**

The animals which were referred to the clinic directly after dystocia or which show wound dehiscence 15-20 days after immediate repair receive immediate wound care and dressing to guard against infection. Prophylactic doses of antitetanic serum were administered. Daily dressing of

the perineal injuries were performed using diluted betadine scrub and topical antibiotic till complete wound contraction and epithelization (Figs. 1A&B). Vaginal and uterine infections were controlled before surgical interference using uterine wash with diluted betadine, topical intrauterine administration of 4 grams oxytetracycline tablets and parenteral antibiotics (penicillin - streptomycine) was applied. The animals were fed on green fodders and bran mash one week before surgery.

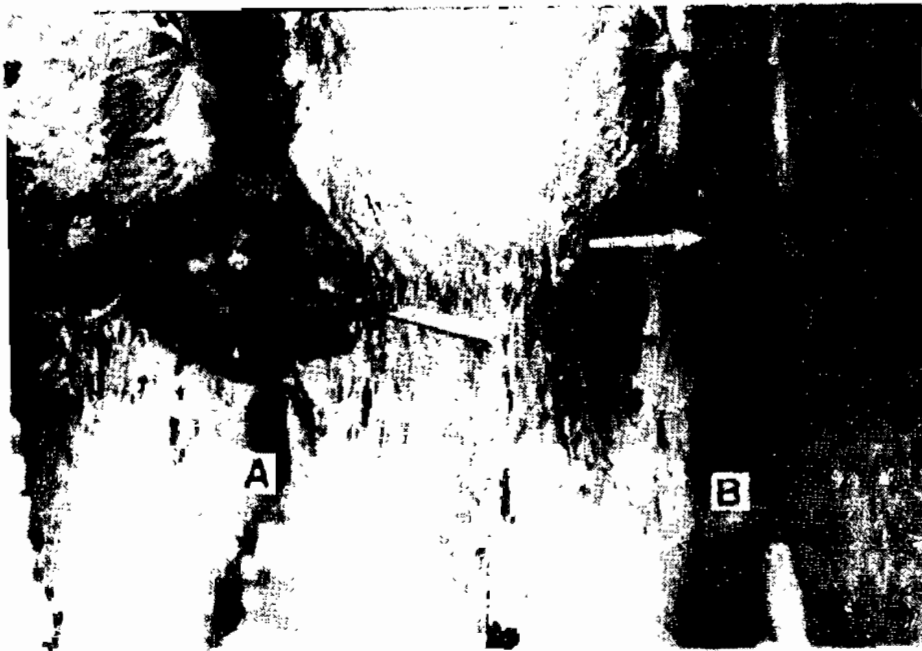In preparation for surgical interference, the food was withheld for about 24 hours. The entire tailhead, buttocks, and perineum were prepared aseptically. The tail was wrapped and reflected dorsally, fecal material from the rectum was removed as cranial as possible. A prepared plug of gauze & cotton covered with zinc oxide ointment attached with a long tape of gauze was inserted into the cranial rectum to absorb faecal fluid and prevent faecal contamination of the surgical site. The tissues were cleansed with diluted betadine scrub and prepared for aseptic surgery .

#### **Surgical Approach :**

The surgical intervention was performed in one stage on standing animals restrained in a stock under sedation with combelen and caudal epidural analgesia using 6-10 ml of 2% lidocaine hydrochloride (Lignocaine, Trittau-Germany). The ventral anal sphincter and dorsal vulval commissure were retracted laterally by two Allis tissue forceps placed in the margins of the old wound. The dissection was made in a horizontal plane starting in the retracted, remnants shelf of the rectovaginal septum. The shelf was split from side to side by both scissors and scalpel leaving a more thicker rectal flap than the vestibular one to allow suturing without tension (Fig. 2A). The shelf between rectum and vestibule (phase 1) was reconstructed using the modified Goetz pattern as reported by **Straub & Fowler, (1961)** by six-bite vertical interrupted mattress sutures using size 2 Polydioxanone (Fig. 2B). The second phase of dissection extended downward from the horizontal plane in a triangular fashion to expose the scarred end of the divided muscle fibers of the perineal body (Fig. 3A). These freshened surfaces and cutaneous perineum were closed using a combination of interrupted vertical mattress sutures for tension and simple interrupted suture for apposition of the skin. PDS was used for deeper tissues and multifilament silk for the skin and a Caslick vulvoplasty was completed (Figs. 3B&C).

#### **Postoperative Management :**

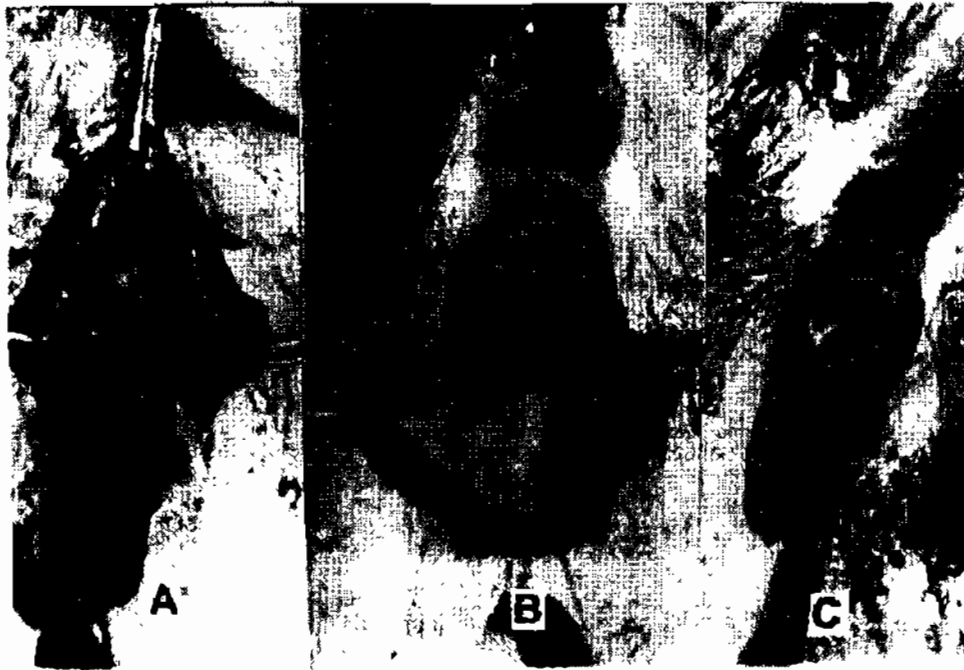Prophylactic doses of antitetanic serum were given beside topical antibacterial ointment. Parenteral administration of the antibiotics as well as non-steroidal anti-inflammatory drug (phenylbutazone 5mg / kg B. W.) were given for 5 successive days. The preoperative diet was continued for two weeks postoperatively. The skin sutures were removed after 10-12 days.



**Fig. 1** : A she donkey with third-degree rectovestibular laceration 15 days after immediate surgical interference. Note complete disruption of the perineal body, anal sphincter and rectal and vestibular walls(A) . Six weeks after dressing showing third-degree perineal laceration sufficiently healed allowing the second surgical interference (B).



**Fig. 2** : Showing initial separation of the rectovestibular shelf (A). After reconstruction of the shelf (phase I) (B).



**Fig. 3 :** Showing the exposure of the perineal body( A ). After complete reconstruction of the perineal body (phase II) ( B & C ) .

### RESULTS

Third-degree rectovestibular lacerations were diagnosed in 6 mares and a she donkey. Six of these animals were primiparous while the last mare was multiparous. These cases were presented with a common opening between the vaginal vestibule and rectum. Feces were seen constantly contaminating the vaginal cavity and occasional unpleasant sound from air sucking with its movement. Clinic examination revealed disruption of the perineal body, anal sphincter, floor of the rectum and roof of the vestibule and vagina. The septum between rectum and vestibule was completely torn and seemed to be as a contracted scar tissue far from the surface of the perineum by about 5-7 cm. distance cranially. Literal devitalization of the anus and vulvar lips was seen and the tissues do not sharply divided but were torn apart in eccentric planes. The superficial layers were infected (Figs.4A & B). The injury caused minimal upset to the animal's general constitution. Chronic cases showed mucopurulent vaginal discharge and pneumovagina.

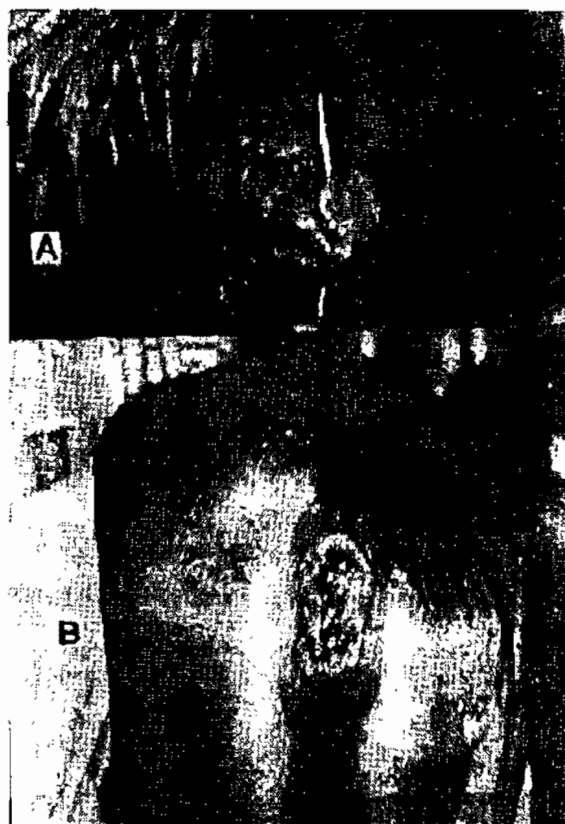Frequent dressing for the wounds of the cases admitted after injury or the recurrent one after immediate reconstruction showed that the raw surfaces were covered with healthy granulations. The margins epithelialized and dimensions of the wound surface reduced by contraction. Complete disappearance of wound edema with partial healing of the anus and perineal bodies was demonstrated (Figs. 5A&B , 6A&B, 7A&B).

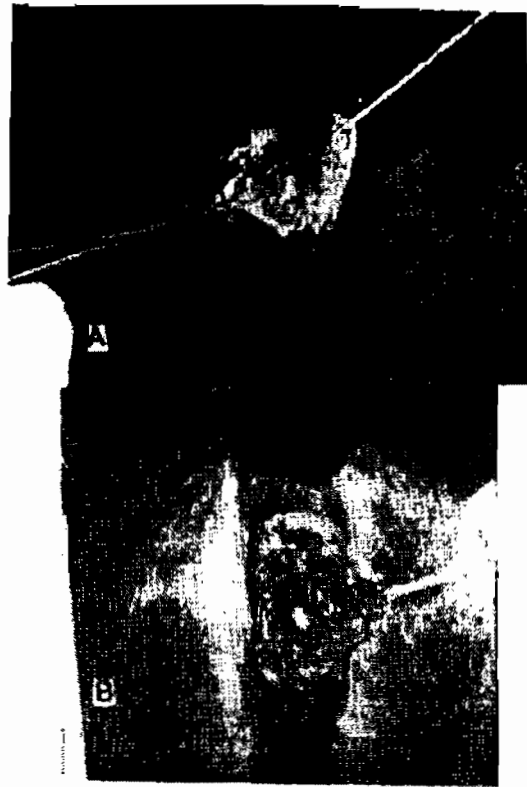The reconstruction was performed most easily on the standing sedated animals in a stock under posterior epidural anesthesia. This means of restraint proved effective in controlling the dead cases and no additional anaesthesia was needed. The reconstruction was completed in a single operation where the field was retracted with Allis tissue forceps. Dissection of the rectovaginal septum and exposure of the perineal body was achieved by submucosal resection. The shelf between the rectum and vestibule was reconstructed followed by reconstruction of the perineal body, anus and vulva (Figs.8A&B, 9A&B).

The suturing patterns and the suturing materials used in the present work proved to be highly efficient in reconstructing the rectovestibular shelves as well as restoration of a functional perineal bodies.


Transient wound edema was noticed after operations, which elapsed after 3-5 days. Primary healing of the rectovestibular shelves with intact perineal bodies was obtained in 6 animals although one mare showed a remarkable anal sphincter incompetence. One mare developed a rectovestibular fistula owing to severe straining 15 days postoperation. In the latter the tissues between rectum and vestibule were completely perforated however the perineal body remains intact (Fig. 10). The operated animals had not allowed to be bred naturally unless 4-6 months had elapsed after surgical interference.

**Fig. 4 :** Third-degree rectovestibular laceration in a pluriparous mare 5 days after injury. Note the disruption of the rectal and vestibular walls, anal sphincter, rectovestibular shelf and partial tearing of the perineal body (A). Third-degree perineal laceration in a primiparous mare 20 days after immediate interference showing complete dehiscence of both rectovestibular shelf and perineal body (B).



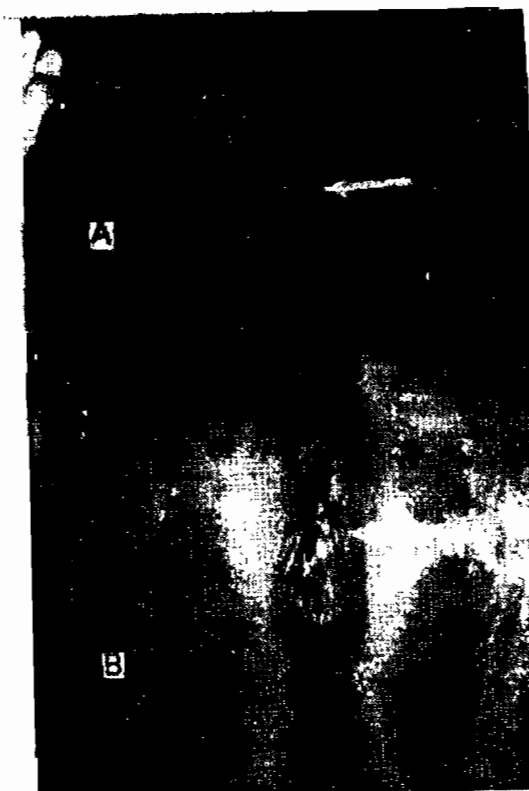


**Fig. 5 : (A & B) :** The same case in Fig. 1 (A & B) after the first dressing with the appearance of healthy granulation tissues.




**Fig. 6 : (A & B) :** The same case in Fig. 2A at 3 weeks (A) and 4 weeks (B) after dressing showing a healthy granulation of the wound edge with partial healing of the perineal body.

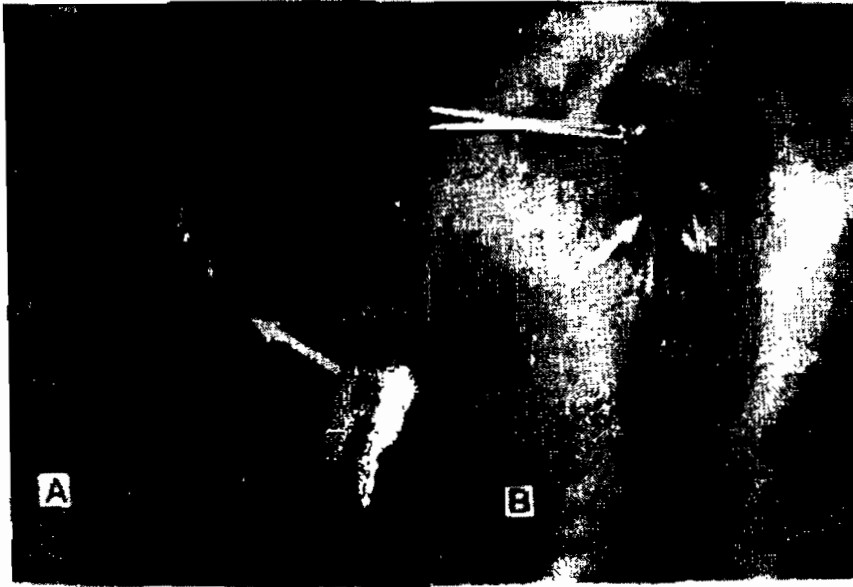
**Fig. 7 :** (A & B) : The same case in fig. 2(A&B) at six weeks after injury and dressing showing complete wound healing that permit successful surgical attempt.



**Fig. 8 :** Showing the dissection along the retracted rectovaginal septum by stab incision that separate a thick rectum from the vestibule(A); After reconstruction of the rectovestibular shelf (B).







**Fig. 9 (A & B) :** After complete reconstruction of the perineal bodies.



**Fig. 10 :** A mare showing a rectovesicular fistula at 3 months after repair of third-degree rectovestibular laceration. Not the intact perineal body.

## DISCUSSION

Third-degree injuries result in disruption of the perineal body, anal sphincter, floor of the rectum and ceiling of the vestibule. The result is a common opening between the vestibule and rectum. The injury results from perforation of the vagina and rectum by one or two feet of the foal during parturition. (Aanes, 1968 and Embertson, 1990). It results in faecal contamination of the mare's vagina with subsequent bacterial infection of the vagina, cervix and uterus. Pneumovagina was diagnosed in longstanding cases with vaginitis, cervicitis and endometritis. Similar observations were reported by **Pourel (1982); Trotter (1992) and Schumacher et al., (1992)**.

The rectovestibular lacerations occurs in a lot of species but is reported with higher frequency in mares than in other domestic animals due to violent efforts of expulsion of the fetus during parturition (**Colbern et al., 1985 and Vaughan, 1988**). The injury causes minimal upset to the animal's general constitution. Frequent dressing and healing by second intention proceeds successfully as the raw surfaces covered with healthy granulation. The margins epithelialize and the dimension of the wound surface reduced by contraction. This is agreed with the findings of **Colbern et al. (1995); Vaughan (1988); Belknap & Nickels (1992); Trotter (1992) and El-Sedawy (1993)** who added that the injury occur more often in mares with excitable temperament, fetal malposition, large foetal size or aggressive assistance during delivery.

Owing to the nature of the injury, bruising trauma was usually extensive. Immediate repair of third-degree perineal laceration in a mare and she donkey results in failure and recurrence after 15-20 days. However, definitive repair was delayed for 5-7 weeks after injury to allow for resolution of inflammation associated with acute trauma also for wound contraction and epithelization of tissue used for septum reconstruction. Similar surgical manœuvres were described by **Straub & Fowler (1961); Aanes (1962 & 1964); Vaughan (1988) and Held & Blackford (1997)**. Acute repair of third-degree injuries should be considered only as described by **Trotter (1992) and Adams et al. (1996)** if they can be performed within few hours and if local damage seen compatible with success.

The surgical repair was done more easily in standing sedated animals under the effect of caudal epidural anaesthesia with all structure laying or supported in proper relationships. One epidural injection was sufficient for 1- 1.5 hours required for the repair. The same was conducted by **Vaughan (1984 & 1986), El-Seddawy (1993), Farag et al. (2000) and El-Maghraby (2002)** However **Walker & Vaughan (1980) and Salch et al (1986)** used dorsal recumbency under the effect of general anaesthesia with successful outcome. While **Adams and Fessler, (2000)** mentioned that dorsal positioning of the patient completely distorts the anatomic relationships and is not recommended. They added that general anaesthesia and sternal positioning have been used.

The traditional two-stage repair was designed by **Ansari & Martos (1983); Colbern et al. (1985); Aanes (1988) and El-Sedawy (1993)** to minimize obstipation during the early postoperative period that could compromise the repair. The first stage involved the reconstruction of the rectovestibular shelf but without closure of most of the perineal body. This was followed 3-4 weeks later by the second repair of the perineal body.

In the present study, the entire repair was performed as a single operation where two tissue shelves were created in the retracted rectovestibular septum with thicker rectal flap than the vestibular one and exposure of the perineal body. By sequencing the dissection and reconstruction, contamination and exposure of the dissected surfaces were kept to a minimum. The dissection was sufficiently deepened into sides of the defect to free the flap in each side that could be brought together in the midline without tension as described by **Stickle et al. (1979) Walker & Vaughan (1980) Belknap & Nickels (1992) and Trotter (1993)** who added that a common error was to make division of the tissue planes too shallow resulting in excessive tension on the edge of the tissue when they are brought into apposition by suture causing either wound dehiscence or fistulate. Although the blood supply to the region was good, the dissection rarely involves larger bleeder or serious hemorrhage and no ligatures were required.

The suture pattern in the cranial part of dissection was interrupted six bite vertical mattress sutures that apposes the rectal mucosa and everted the vestibular mucosa into the vestibule starting in the left vaginal flap using PDS. While the functional perineal bodies were reconstructed by a combination of vertical mattress and simple interrupted sutures for optimum tension and apposition. This suture pattern do not pierce the rectal mucous to avoid its irritation. Similar procedures were conducted by **Stickle et al. (1979); Vaughan (1988)**. However **Belknap & Nickels (1992) and Huber (1998)** advised additional suturing to the rectal mucosa; while in the present study only the six-bite pattern was adequate to prevent leakage of the faecal material into deeper tissues.

In the present investigation all cases occurred at parturition following dystocia. Of the 7 animals 6 were primiparous. This could be attributed as mentioned by **McKinnon et al. (1991); Belknap & Nickels (1992); Hull (1995) and Mair et al. (1998)** to prominent annular fold at the vaginovevstibular junction which could be caught by the foal front foot or nose.

Various suture materials have been used for repair of the third-degree rectovestibular lacerations as monofilament nylon (**Stickel, et al., 1979**), chromic cat gut (**Colbern, et al., 1985**), polyglycolic acid (**Shokry, et al., 1986 and El-Seddawy, 1993**) and polyglactin 910 (**Ibrahim, 1996; Farag, et al., 2000 and El-Maghraby 2002**). The effect of the used suture materials on the outcome of surgical reconstruction in the present study can not be evaluated due to the use

of polydioxanone suture alone.

Although a mare developed sphincter incompetence a successful reconstruction of the recto-vestibular shelves was achieved in six animals. However the partial wound dehiscence in a mare with subsequent development of rectovestibular fistula with intact perineal body could be attributed as mentioned by **Walker & Vaughan, (1980); Trotter (1992); El-Seedawy (1993); Mair et al. (1998) and Farag et al. (2000) El-Maghraby (2002) and Abdel-Wahed (2003).** to severe constipation and straining on defecation..

**REFERENCES**

- Aanes, W. A. (1962)** : The repair of third-degree perineal lacerations and rectovaginal fistulae in the mare. *Am. Assoc. Equine Pract.* 8, 165-169.
- Aanes, W. A. (1964)** : Surgical repair of third-degree perineal laceration and rectovestibular fistulae in the mare. *J Am Vet Med Assoc.* 144, 485-491.
- Aanes, W. A. (1998)** : Surgical management of foaling injuries. *Vet Clin North Am. Equine Pract.* 4, 417-425.
- Abdel-Wahed, R. E. (2003)** : Surgical management of some equine affections related to perineal and inguinal regions. *J Egypt. Vet. Med. Assoc.* 63,( 3): 1-16.
- Adams, S. B. and Fessler, J. F. (2000)** : Atlas of Equine Surgery. 1st ed. W.B Saunders Co., Philadelphia, p 241-244.
- Adams, S. B.; Binker, F. and Brandenburg, T. (1996)** : Direct rectovestibular fistula repair in five mares. *Proc. Am. Assoc. Equine Practitioners.* 42, p 156-159.
- Ansari, M. M. and Martos, L. E. (1983)** : Surgical repair of rectovestibular lacerations in mares. *Compend. Cont. Equine Praet. Vet.* 5, 129-134.
- Belknap J. K. and Nickels, F. A. (1992)** : A one-stage repair of third-degree perineal lacerations and rectovestibular fistulae in 17 mares. *Veterinary Surgery* 21, 378-381.
- Colbern, G. T.; Aanes W. A.; Stashak T. S. (1985)** : Surgical management of perineal lacerations and rectovestibular fistulae in the mare: A retrospective study of 47 cases. *J. Am. Vet. Med. Assoc.* 186, 265-269.
- El-Maghraby, H. M. (2002)** : A retrospective study on some surgical affections of the perineum and vagina in farm animals. *Zag. Vet J.* 30. (3) : 84-100.
- El-Seddawy, F. D. (1993)** : Surgical repair of perineal lacerations in mares and Friesian cows. *J Egypt. Vet. Med. Ass.* 53, (4): 681-691.
- Embertson, R. H. (1990)** : Perineal lacerations. In current practice of equine surgery. Edited by White N.A. and Moore J.N. Philadelphia, J.B. Lippincott, p 669-704.
- Farag, K. A.; Berbish, E. A. and Gohoneim, I. M. (2000)** : A one-stage repair of third-degree rectovestibular lacerations in the mare: An experimental and clinical study. *J Egypt. Vet. Med. Ass.* 60 (2) : 143-151.
- Held J. P. and Blackford J. T. (1997)** : Surgical correction of abnormalities of the female reproductive organs. In *Current Therapy in Large Animal Theriogenology*. Edited by Young-

quist R.S., W. B. Saunders Co., Philadelphia, p 195-208.

**Huber M. J. (1998)** : Modified technique for single rectovestibular fistula closure in three mares  
Equine Vet J 30, 82-84.

**Hull, B. L. (1995)** : Female reproductive surgery. Vet. Clinics of North America: Food Animal  
Practice. I. ( 1): 37-53.

**Ibrahim, I. M. (1996)** : Contribution to reconstruction of third-degree rectovestibular lacerations in mares. Saudi Biological Society (SBS). Seventeenth Annual Meeting on "Biological Natural Resources" in Kingdom of Saudi Arabia.

**Malr, T.; Love, S.; Schumacher, J. and Watson, E. (1998)** : Equine medicine, surgery and reproduction. 1<sup>st</sup> ed. W.B. Saunders Co., Philadelphia, p 177-179.

**McKinnon A. O.; Belden J. O. and Vasey J. R. (1991)** : Selected reproductive surgery of the broodmare. Equine Reproduction: A seminar for veterinarians. Sydney Post Graduate Committee in Veterinary Science 174:109-125

**Pouret, E. J. M. (1982)** : Surgical technique for the correction of pneumo and Urovagina.  
Equine Vet J 14.( 3): 249-250.

**Saleh, M. S.; Gohar, H. M.; El-Keley, M. T.; Ibrahim, I. M. and Abdel-Hamid M. A. (1988)** : Reconstruction of a third-degree rectovestibular laceration in an Arabian mare. J. Egypt. Vet. Med. Ass. 48 (4) : 629-635.

**Schumacher, J.; Schumacher, J. and Balanebard, T. (1992)** : Comparison of endometrium before and after repair of third-degree rectovestibular lacerations in mares. J Am. Vet. Med. Assoc. 200 (9): 1336-1338.

**Shokry, M.; Ibrahim, I. M.; Ahmed, A. S. and Abdel-Hamid, M. A. (1986)** : Preferred suture material in repair of rectovestibular lacerations in mares. Modern Veterinary Practice. 3. 546.

**Stickel, R. L. Fessler, J. F.; Adams, S. B. (1979)** : A single-stage technique for repair of rectovestibular lacerations in the mare. Veterinary Surgery 8, 25-27.

**Straub, O. C.; Fowler, M. E. (1981)** : Repair of perineal lacerations in mare and cow. J. Am. Vet. Med. Assoc. 138, 659-663.

**Trotter, G. W. (1992)** : Surgical diseases of the caudal reproductive tract. In: Equine Surgery. 1<sup>st</sup> ed., by Aucr, J.A., W.B. Saunders Co., Philadelphia, p 740.

- Trotter, G. W. (1993)** : Surgery of the perineum in the mare. In Equine Reproduction. 1 st ed. by Mckinnon, A.O. and Voss, J.L. Lea & Febiger, Philadelphia, p 417-427.
- Vaughan, J. T. (1984)** : Equine Urogenital system. In Jennings P.B. The practice of large animal surgery. V. 2, W.B. Saunder Co., Philadelphia., p 1122-1150.
- Vaughan, J. T. (1986)** : Equine urogenital system. In Morrow D.A. (ED): Current Therapy in Theriogenology. Philadelphia, W.B. Saunders Company, p 756.
- Vaughan, J. T. (1988)** : The female genital system: In Oehme, F.W. Textbook of Large Animal Surgery. 2 nd ed. Baltimore, Williams & Wilkins, p 559-584.
- Walker, D. F. and Vaughan J. T. (1980)** : Bovine and Equine Urogenital Surgery. ed. Lea & Febiger, Philadelphia, p 201-210.

الملخص العربي

التقويم الجراحي لتهتكات العجان من الدرجة الثالثة فى الفصيلة الخيلية

المشركون فى البحث

جمال إبراهيم عبدالفتاح قرور و عادل التابعى إبراهيم زغلول

قسم الجراحة والتخدير والأشعة - كلية الطب البيطرى - جامعة المنصورة

أجريت هذه الدراسة على ستة أفراس مختلفة الأجناس وكذلك عدد حمارة واحدة تتراوح أعمارهم بين ٣-٧ سنوات. كانت هذه الحيوانات تعاني من تهتكات من الدرجة الثالثة بالمنطقة العجانية بعد معاناتها من عسر أثناء الولادة. تم التدخل الجراحى مباشرة بعد حوالى ١٢-٢٤ ساعة فى حالتين لفرس وحمارة، هذا وقد حدث تهتك مرة أخرى بعد حوالى ١٥-٢٠ يوم من التدخل الجراحى وتم التدخل جراحياً مرة أخرى بعد ٥-٧ أسابيع. أما بقية الأفراس فقد تم التدخل الجراحى بعد حوالى ٥-٧ أسابيع من خلال إعادة تكريين الهاجز بين المستقيم والمهبل وإعادة بناء إلتنام شفتى المهبل والجسم العجانى وذلك بالطريقة التجديدية العمودية المتقطعة ذات الست دخلات باستخدام مادة البولى دايكينون (PDS). هذا وقد تم الإلتنام بنجاح بالقصد الأول فى جميع الحيوانات ماعدا فرس تعرضت للتهتك مرة أخرى بعد التدخل الجراحى وذلك يرجع للتحزيف المستمر بعد حوالى ١٥ يوم من العملية. هذا وقد سجلت مختلف نتائج هذه الدراسة وتم مناقشتها تفصيلاً.